# Children's Hospital of Pittsburgh

# Annual Progress Report: 2008 Formula Grant

**Reporting Period**

July 1, 2010 – June 30, 2011

**Formula Grant Overview**

The Children's Hospital of Pittsburgh received $958,038 in formula funds for the grant award period January 1, 2009 through December 31, 2012. Accomplishments for the reporting period are described below.

**Research Project 1: Project Title and Purpose**

*A Genetic Model of Congenital Obstructive Nephropathy* - End-stage kidney disease costs over 15 billion dollars annually in the United States and represents a major cause of death and impaired quality of life. The long-term objective of this project is to gain a better understanding of the most common cause of kidney disease in children - a blockage in urine flow. Completion of the studies outlined in this proposal will help us design new diagnostic tests and treatment strategies for children and adults with kidney disease.

**Anticipated Duration of Project**

1/1/2009 - 12/31/2012

**Project Overview**

In utero obstructive nephropathy has the potential to interrupt normal renal development and represents the most common cause of chronic renal failure in children. The long-term objective of this project is to gain a better understanding of the pathophysiology of in utero obstructive nephropathy as it relates to normal kidney development in an effort to identify potential therapeutic pathways for intervention. We have identified a highly unique mutant mouse model, designated mgb, for megabladder, that develops overt signs of lower urinary tract obstruction in utero resulting in the development of hydroureteronephrosis and progressive renal failure. In this project, we will utilize the mgb mouse model to: 1) complete characterization of the development of in utero obstructive nephropathy in the mgb mouse including the identification of pathophysiological changes associated with kidney development, 2) identify and characterize the role that transforming growth factor β (TGF-β) signaling plays in mediating renal injury in the mgb mouse model of in utero obstructive nephropathy, and 3) develop and assess therapeutic strategies designed to ameliorate renal injury in the mgb mouse model of in utero obstructive nephropathy. The identification and characterization of the factors responsible for the pathogenic changes in renal function following the development of congenital bilateral obstructive nephropathy in mgb mice will provide a platform for the evaluation of pharmacological, surgical,

and gene therapy strategies designed to prevent and treat the pathogenic processes associated with the development of progressive renal failure in utero.

**Principal Investigator**

Carlton M. Bates, MD
Associate Professor
Children's Hospital of Pittsburgh
3705 Fifth Avenue
Pittsburgh, PA 15213

**Other Participating Researchers**

None

**Expected Research Outcomes and Benefits**

At present, the only therapy for babies born with blockage of urine flow is surgery. Unfortunately, approximately 50% go on to complete kidney failure despite the surgery (due to damage that occurs in the womb). In addition to the high costs of kidney failure, 25-50% of babies born with complete kidney failure will die before their first birthday (despite dialysis or kidney transplantation).

We now have a unique mouse model that develops blockage of urine before birth. Remarkably, when we perform surgery to relieve the blockage, about 50% of them survive (just like children born with urinary blockage). This gives us an opportunity to learn more about why some children do well with surgery and others do not. It also gives us chances to explore what drugs we can use before birth to improve kidney survival after surgery. What we learn from this very unique model can be used to improve survival and quality of life of children born with blockage of urine flow.

**Summary of Research Completed:**

The progress report will be divided according to the specific aims of the application:

Specific Aim 1. Complete characterization of the development of *in utero* obstructive nephropathy in the *mgb* mouse including the identification of pathophysiological changes associated with kidney development.

Further characterization of kidney anomalies:
In the previous reporting period, we had begun to use renal ultrasonography as means of stratifying renal injury in post-natal megabladder (*mgb-/-*) mice. Since then, we have refined the technique in larger numbers of mice and have used this technique now in embryonic mice. As shown in Figure 1, we used renal ultrasonography (RUS) to stratify increases in mutant renal pelvic anterior-posterior diameter (APD) into mild, moderate, and severe categories of hydronephrosis in mice at 14, 18, and 35 days of age. While we did not observe evidence of

hydronephrosis in utero at embryonic day 15.5 (E15.5), we did detect hydronephrosis in mutants by RUS at E17.5. As shown in Table 1, three dimensional reconstructions from RUS images in E17.5 mutants show significant increases in renal pelvic volume (normalized to total kidney volume) in both right and left kidneys. Newborn mutant mice also uniformly showed mild to moderate hydronephrosis on renal ultrasonography. At the end of the renal ultrasonography, we euthanized animals and confirmed that the apparent hydronephrosis seen on RUS correlated with real hydronephrosis by direct observation.

We also were able to quantify degrees of fibrosis in *mgb-/-* kidney (by Trichrome staining), as sampled over many regions of the kidneys. In controls, mean percentage of fibrosis in the outer cortex and inner medulla were 4.5% and 4.2% respectively. In comparison, mildly affected mutants (stratified by hydronephrosis) had 10.1% and 15.3% mean percentages of fibrosis in the outer cortex and inner medulla, respectively. Severely affected mutants had 45.2% and 85.5% mean percentages of fibrosis in the cortex and medulla, respectively. These findings are important given that it further validates the disease stratification made by RUS.

Other observations noted in the current reporting period are that many of the mutant *mgb-/-* adult kidneys developed additional signs of chronic injury and/or dysplasia (Figure 2). Among these included simple cysts and multiple cysts within the tubules. Many mutant kidneys also contained proteinaceous casts indicative of severe kidney injury. Trichrome staining revealed that many kidneys had sclerotic glomeruli. Regions of other *mgb-/-* kidneys showed evidence of coagulation necrosis. These findings are important given that these findings are often seen in patients with congenital obstructive nephropathy as in the case of patients with posterior urethral valves.

While we had previously reported scattered interstitial infiltration of macrophages in many of the adult mutant mice, in mutants that were aged longer and more severely affected, we detected different patterns of inflammation (Figure 3). As shown, more severely affected mutants had more a more significant chronic inflammatory response, often adjacent atrophic and/or dilated/cystic tubules (panels A, B). Some of the mutants also developed micro-abscesses within the cortex (panel C). Many of these cells appeared to be plasma cells, including Russell bodies (plasma cells with large eosinophilic immunoglobulin inclusions) (panel D). These findings could be secondary to infection as is often the case in patients with chronic obstructive nephropathy.

<u>Specific Aim 2</u>. Identify and characterize the role that TGF-β signaling plays in mediating renal injury in the *mgb-/-* mouse model of *in utero* obstructive nephropathy.

We have completed expression patterns of TGF-β and its downstream targets such as CTGF in previous funding cycles.

<u>Specific Aim 3.</u> Develop and assess therapeutic strategies designed to ameliorate renal injury in the *mgb-/-* mouse model of *in utero* obstructive nephropathy**.**

We have had no additional progress on this section since the previous funding period.

**Figures and Tables:**

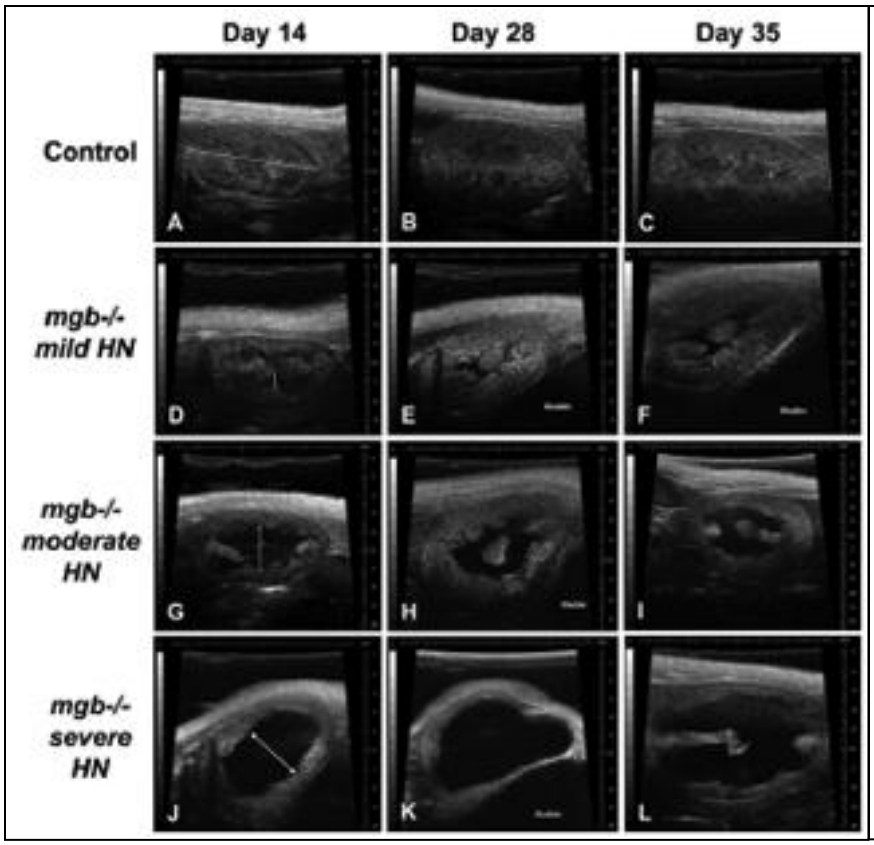


**Figure 1: Renal ultrasonography showing differences in *mgb-/-* mutant hydro-nephrosis (HN) at 14, 28, and 35 days of age.** A-C. Controls with normal appearing kidneys including no hydronephrosis. D-F. *mgb-/-* mice with mild hydronephrosis. G-I. mutant mice with moderate hydro-nephrosis. J-L. mutant mice with severe hydro-nephrosis. Please note that the double-headed arrows in D, G, and J indicate the pelvic APD.

Table 1: Total kidney volume vs renal pelvic volume by 3D reconstruction in E17.5 kidneys

| | *mgb-/-* right | *mgb-/-* left | control right | control left |
|---|---|---|---|---|
| kidney volume ($\mu m^3$) | $2.10 \times 10^9$ | $1.85 \times 10^9$ | $1.34 \times 10^9$ | $1.29 \times 10^9$ |
| pelvic volume ($\mu m^3$) | $8.67 \times 10^7$ | $6.27 \times 10^7$ | $1.32 \times 10^7$ | $1.31 \times 10^7$ |
| pelvic volume/ kidney volume (normalized to 1 in controls) | 4.1* | 3.4* | 1.0 | 1.0 |

* $p = 0.018$

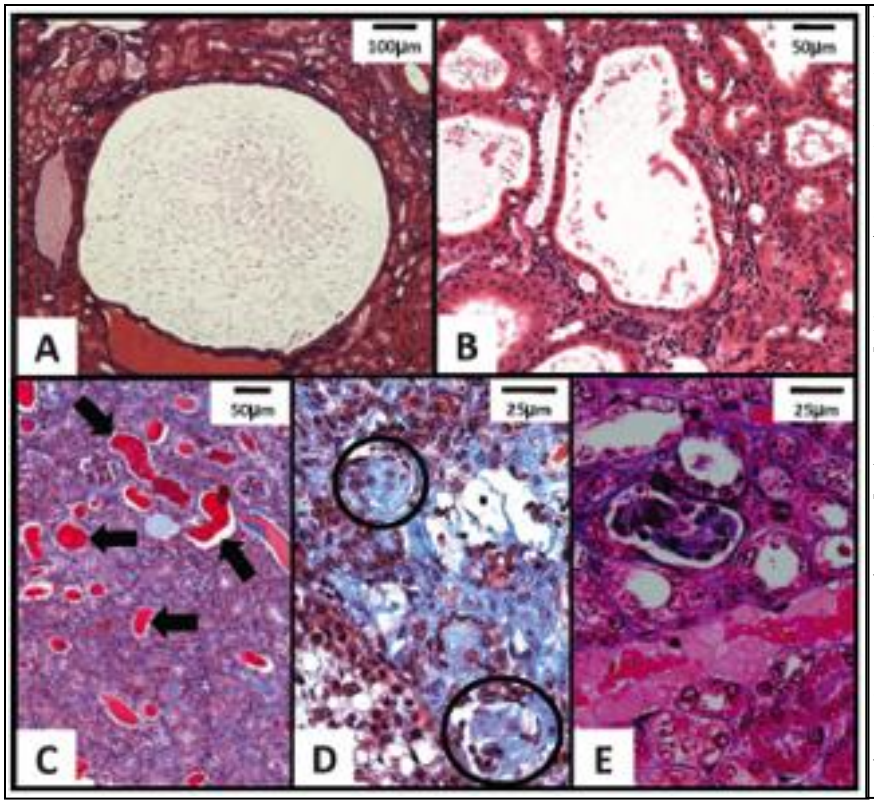


**Figure 2: Adult *mgb-/-* kidneys have features of dysplasia and chronic kidney disease.** A, B. H&E staining shows severely affected kidneys (stratified by hydronephsis) with simple cysts (A) and multiple cysts (B). C. Trichrome staining in a severely affected kidney shows many proteinaceous tubular casts (arrows). D. Trichrome stain shows a severely affected kidney with globally sclerotic glomeruli (circles). E. H&E stain shows a moderately affected kidney with coagulation necrosis and vacuolization of tubules

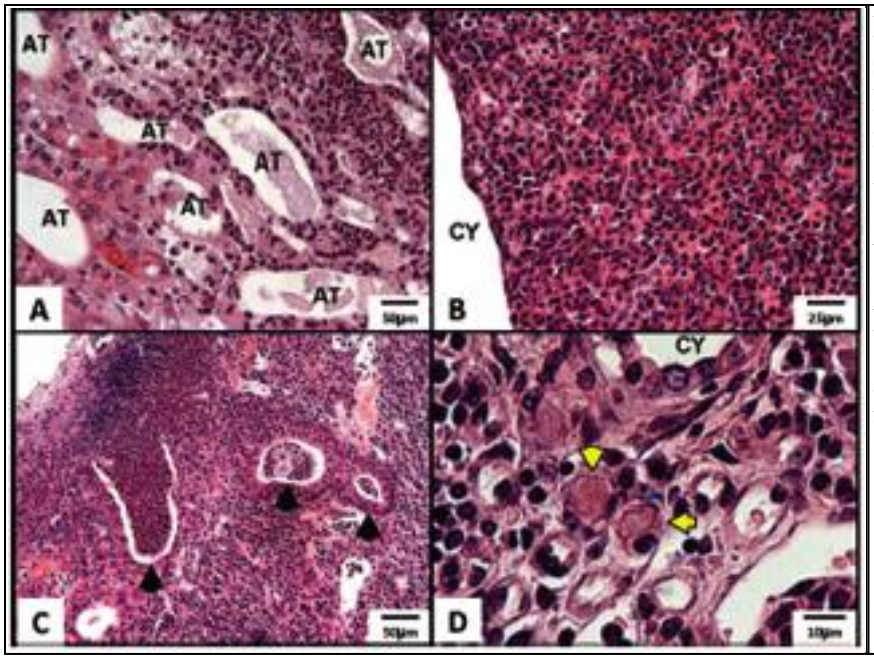


**Figure 3: Adult mgb-/- severely affected kidneys have significant inflammation.** A, B. Sheets of inflammatory infiltrates surround dilated atrophic tubules (A) and cysts (B). C. Many mutant kidneys have microabscesses. D. Some mutant kidneys have plasma cells including Russell bodies (yellow arrows).