Children's Hospital of Pittsburgh

Annual Progress Report: 2008 Formula Grant

Reporting Period

July 1, 2009 – June 30, 2010

Formula Grant Overview

The Children's Hospital of Pittsburgh received $958,038 in formula funds for the grant award period January 1, 2009 through December 31, 2012. Accomplishments for the reporting period are described below.

Research Project 1: Project Title and Purpose

A Genetic Model of Congenital Obstructive Nephropathy - End-stage kidney disease costs over 15 billion dollars annually in the United States and represents a major cause of death and impaired quality of life. The long-term objective of this project is to gain a better understanding of the most common cause of kidney disease in children - a blockage in urine flow. Completion of the studies outlined in this proposal will help us design new diagnostic tests and treatment strategies for children and adults with kidney disease.

Anticipated Duration of Project

1/1/2009 - 12/31/2012

Project Overview

In utero obstructive nephropathy has the potential to interrupt normal renal development and represents the most common cause of chronic renal failure in children. The long-term objective of this project is to gain a better understanding of the pathophysiology of in utero obstructive nephropathy as it relates to normal kidney development in an effort to identify potential therapeutic pathways for intervention. We have identified a highly unique mutant mouse model, designated mgb, for megabladder, that develops overt signs of lower urinary tract obstruction in utero resulting in the development of hydroureteronephrosis and progressive renal failure. In this project, we will utilize the mgb mouse model to: 1) complete characterization of the development of in utero obstructive nephropathy in the mgb mouse including the identification of pathophysiological changes associated with kidney development, 2) identify and characterize the role that transforming growth factor β (TGF-β) signaling plays in mediating renal injury in the mgb mouse model of in utero obstructive nephropathy, and 3) develop and assess therapeutic strategies designed to ameliorate renal injury in the mgb mouse model of in utero obstructive nephropathy. The identification and characterization of the factors responsible for the pathogenic changes in renal function following the development of congenital bilateral obstructive nephropathy in mgb mice will provide a platform for the evaluation of pharmacological, surgical,

and gene therapy strategies designed to prevent and treat the pathogenic processes associated with the development of progressive renal failure in utero.

Principal Investigator

Carlton M. Bates, MD
Associate Professor
Children's Hospital of Pittsburgh
3705 Fifth Avenue
Pittsburgh, PA 15213

Other Participating Researchers

None

Expected Research Outcomes and Benefits

At present, the only therapy for babies born with blockage of urine flow is surgery. Unfortunately, approximately 50% go on to complete kidney failure despite the surgery (due to damage that occurs in the womb). In addition to the high costs of kidney failure, 25-50% of babies born with complete kidney failure will die before their first birthday (despite dialysis or kidney transplantation).

We now have a unique mouse model that develops blockage of urine before birth. Remarkably, when we perform surgery to relieve the blockage, about 50% of them survive (just like children born with urinary blockage). This gives us an opportunity to learn more about why some children do well with surgery and others do not. It also gives us chances to explore what drugs we can use before birth to improve kidney survival after surgery. What we learn from this very unique model can be used to improve survival and quality of life of children born with blockage of urine flow.

Summary of Research Completed

Specific Aim 1. Complete characterization of the development of *in utero* obstructive nephropathy in the *mgb* mouse including the identification of pathophysiological changes associated with kidney development.

Disease Stratification:
We stratified renal injury in *mgb-/-* mice using high resolution renal ultrasound (not shown). A total of 18 *mgb-/-* mice and 19 age-matched controls were studied at two, four and five weeks of age. We observed no difference in renal length between control and *mgb-/-* mice at any time point examined. We never observed hydronephrosis in control kidneys. The degree of hydronephrosis progressively worsened during the time course of the study, with 15 of 18 *mgb-/-* mice developing bilateral hydronephrosis and the remaining three showing unilateral hydronephrosis. Renal pelvic anterior-posterior diameter (APD) in *mgb-/-* kidneys was significantly increased bilaterally at all time points, with a majority of right kidneys showing

greater hydronephrosis than the left at each time point. The difference in the degree of left APD between survivors and non-survivors was statistically significant ($p < 0.05$), while the degree of left kidney preservation appeared predictive of demise.

The mgb-/- Mutation Has No Direct Genetic Effect on Kidney Development

At embryonic day 15.5 (E15.5), when the bladder phenotype first becomes evident, all other organ systems including the kidneys appear normal by hematoxylin and eosin staining (Figure 1A, B). Furthermore, we bred *mgb-/-* mice with heterozygous Hoxb7GFP transgenic mice (*Hoxb7Gfp*$^{Tg/+}$) that express green fluorescent protein (GFP) throughout all of the ureteric bud derived structures including the renal collecting ducts, renal pelvis, and ureters. To date, seven mice that were *mgb-/-Hoxb7GFP*$^{Tg/+}$ compound mutants had normal appearing GFP-positive ureteric bud trees at E15.5 (Figure 1C, D). Furthermore, the gene responsible for the *mgb-/-* phenotype has no known role in kidney development or function (not shown). These collective observations indicate that the mutation associated with the development of megabladder in *mgb-/-* mice has no direct genetic effect on kidney development. Therefore, any renal abnormalities seen at later stages of development or post natally are associated with the pathogenic progression of obstructive nephropathy in *mgb-/-* mice.

Urine Output and Serum Chemistry in mgb-/- Mice Is Altered

In general, we observed only modest differences in mean water intake and mean urine output between *mgb* genotypes (not shown). Interestingly, none of the age-matched male *mgb-/-* weanlings examined produced measurable urine in metabolic cages and only one male *mgb-/-* weanling survived the 24-hour testing period. To characterize potential urine output, we percutaneously drained male *mgb-/-* bladders removing an average of 10-15 mls of urine. Male *mgb-/-* bladders refilled with urine within 1-2 hours suggesting the presence of severe concentrating defects. To confirm that the male urethra is patent, we performed percutaneous radiocontrast cystograms on live mice. The cystograms showed grossly enlarged, trilobular bladders in *mgb-/-* mice that indeed extruded contrast reagent through the urethra with sufficient pressure.

To determine degree of kidney injury, we performed blood chemistry profiles on 30 *mgb-/-*, 17 *mgb+/-* and 12 wildtype female mice, and 30 *mgb-/-*, 23 *mgb+/-* and 16 wildtype male mice (Figure 2). We assayed blood urea nitrogen (BUN), creatinine, phosphorus, calcium, sodium, potassium, chloride, bicarbonate, and albumin. We compared individual test results to the median of the corresponding gender wildtypes, and used the magnitude of the log2 ratio to determine the degree of abnormality. We used an exact upper-tailed Wilcoxon rank-sum test to determine whether the abnormality measures were significantly elevated relative to the same gender wildtypes. Individual values are considered significant with an NLP value > 2.3 or a P-value of 0.005. We observed no statistically significant alterations in serum chemistries between any female mice. In contrast, we detected significant increases in BUN, creatinine, calcium, and potassium in male *mgb-/-* mice compared to controls.

Since the temporal course of kidney injury in *mgb-/-* mice is variable, individual serum chemistry values often vary between mutants. Even so, we were able to identify a subset of eight male and four female *mgb-/-* mice that displayed bicarbonate levels <5.0 mmol/L and showed dramatic increases in BUN and creatinine levels (Table 1). These animals were noted as

terminally sick with eight of the twelve showing severe hydronephrosis (four mice were not recorded). Thus, the combined assessment of BUN + creatinine + bicarbonate provides a prognostic marker set that unambiguously identifies mice in the terminal stages of renal failure, which will be important as we track the responses to therapy and validate other potential biomarkers.

Many Histological Markers are Altered in Adult mgb-/- Mice:
F4/80 immunostaining (specific for macrophages) was almost undetectable in adult control kidneys (not shown). In contrast, F4/80 expression in presumptive macrophages progressively increased in moderate to severe adult kidneys, with positively staining cells observed throughout the interstitium and glomeruli (not shown). Thus, there is an inflammatory infiltrate of macrophages within adult *mgb-/-* mice.

Wt-1 immunostaining was also altered in injured *mgb-/-* mice (not shown). Adult control kidneys showed sparse Wt-1 positive cells within their glomeruli, while the glomeruli of severely injured *mgb-/-* kidneys showed a statistically significant increase in Wt-1 positive cells with a distribution similar to that observed in newborn control glomeruli. Thus, Wt-1 may be a biomarker of progressive kidney injury in *mgb-/-* mice.

Pax2 immunostaining was also altered in more severely injured *mgb-/-* mice. In adult control kidneys, Pax2 staining was reduced when compared to newborn control kidneys. Newborn control kidneys showed intense nuclear and diffuse cytoplasmic staining throughout the nephrogenic zone, in a subset of cortical and medullary ducts, and in the urothelium lining the renal pelvis (Fig. 3A-D). Pax2 staining showed a mixed response in severe adult kidneys with some animals displaying high levels of Pax2 staining throughout the renal parenchyma, and the urothelium of the renal pelvis similar to that observed in newborn kidneys (Fig. 3E). Adult control kidneys showed limited Pax2 staining in the cells lining Bowman's capsule (Fig. 3F), while severely injured *mgb-/-* adult kidneys showed a statistically significant increase in the number of Pax2-positive cells lining Bowman's capsule to a level similar to that observed in newborn controls (Fig. 3G, H).

Specific Aim 2. Identify and characterize the role that TGF-β signaling plays in mediating renal injury in the *mgb-/-* mouse model of *in utero* obstructive nephropathy.

Moderately injured *mgb-/-* kidneys showed more intense TGF-β1 expression by immunostaining within cortical ducts, cortical and medullary interstitial cells, and glomeruli compared to controls (Fig. 4A-F). Severely injured kidneys showed expanded TGF-β1 staining in glomeruli, interstitial cells, the capsular epithelium, urothelium of the renal pelvis, and cortical ducts where an apical pattern of expression was observed (Fig. 4G-I). TGF-β1 staining in severe kidneys was also observed surrounding regions of necrosis and within areas containing inflammatory infiltrates (data not shown).

Specific Aim 3. Develop and assess therapeutic strategies designed to ameliorate renal injury in the *mgb-/-* mouse model of *in utero* obstructive nephropathy**.**

Given that the only therapy for patients with obstructive nephropathy is surgical relief of obstruction, we began performing cutaneous cystotomies (percutaneous vesicostomies) in male *mgb-/-* mice to relieve the obstruction. Of the 19 male mgb-/- mice having undergone the procedure, only four died of surgical complications (dehiscence, bladder prolapse, uroperitoneum) and one of a medical complication (Table 2). Thus, we have established that vesicostomy can be performed in mice with few experiencing complications.

Among the 14 mice with no peri-operative complications, 6 (43%) lived several weeks to months after surgery (see Table 2), whereas *mgb-/-* males without surgery die by 5-6 weeks of age. Examination of each animal revealed a patent stoma, well-healed abdominal wall, and no evidence of organ prolapse. Thus, the vesicostomy alone rescues a significant subset of *mgb-/-* mice, confirming that they were dying of renal failure. Some long term survivors also bred well, suggesting significant renal recovery.

The other eight *mgb-/-* male (57%) mice died within 1-2 weeks of surgery, within the time frame that untreated male *mgb-/-* mice die (Table 2). None of these mice had evidence of surgical complications, infection, bleeding, etc. In two cases, we gave mice intraperitoneal saline to try to prevent dehydration. Based on these collective data, we strongly suspect that these mice died of renal failure despite vesicostomy.

Thus approximately 43% (6/14) of the male *mgb-/-* survive as a result of the surgery (excluding those with surgical and medical complications), whereas 57% (8/14) die as they would have without vesicostomy. This strongly mimics what happens in children with obstructive nephropathy, i.e., 30-70% develop end stage renal failure despite surgical intervention (and would die without renal replacement therapy). This model therefore offers the unique opportunity to test adjunctive pharmacologic therapies to augment surgical intervention.

Tables and Figures:

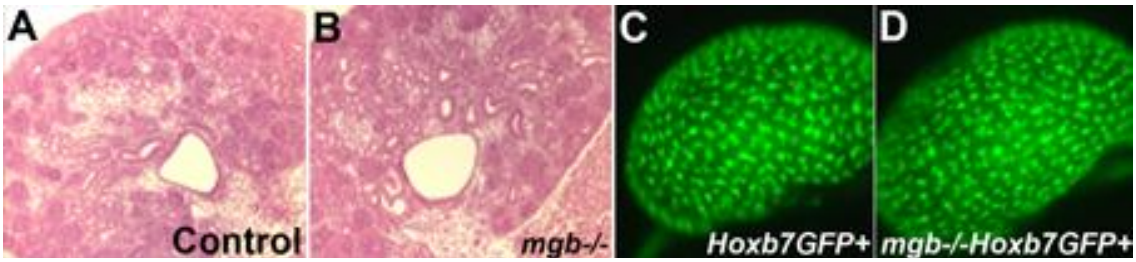

Figure 1. Kidneys appear normal when the *mgb-/-* bladder phenotype first becomes evident at E15.5. Representative Mason's trichrome stains of kidney in E15.5 control (A), and *mgb-/-* (B) mice show normal morphogenesis (50X). Green fluorescent protein (GFP) expression in E15 control *Hoxb7GFP*$^{Tg/+}$ (C) and *mgb-/-Hoxb7GFP*$^{Tg/+}$ (D) mice show that the all ureteric bud-derived structures appear normal.

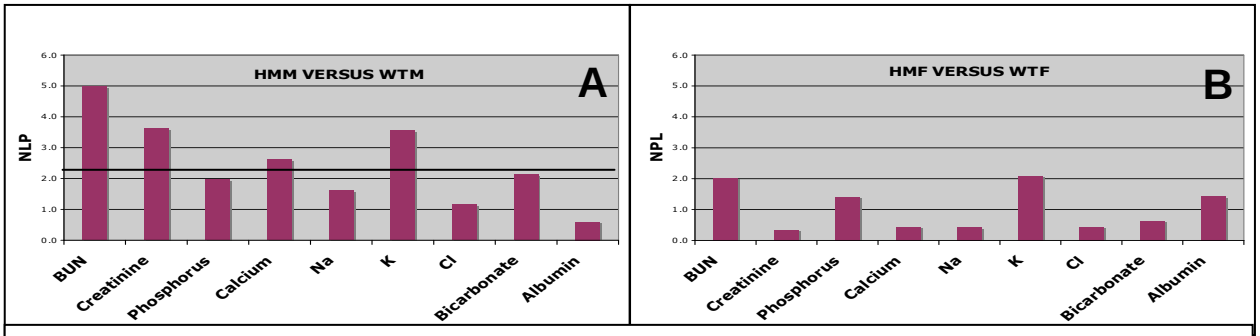

Figure 2. *mgb-/-* mice show altered serum chemistries consistent with chronic renal failure. Statistical analysis of serum chemistry values for *mgb-/-* male (HMM; A) and *mgb-/-* female (HMF; B) versus wildtype control male (WTM) and female (WTF) mice. Alterations are considered statistically significant with a negative Log10 P-value (NLP) value > 2.3, which is a p value <0.005 (A, bold line).

Table 1. Blood chemistry and kidney morphology in male and female *mgb-/-* mice

Genotype[a]	BUN	Creatinine	Phosphorus	Calcium	Na	K	Cl	Bicarbonate	Albumin
0-2 male	**153**	**2.7**	**32.7**	**10.2**	129	**18.3**	87	*<5.0*	*0.21*
0-2 male	**40**	0.4	**12.0**	9.2	132	5.6	84	*<5.0*	2.0
0-2 male	*20*	--	**13.2**	**9.6**	**136**	**6.0**	**88**	*<5.0*	**3.2**
3-4 male	**740**	**11.0**	**94.1**	9.3	*87*	**80.3**	83	*<5.0*	*0.8*
3-4 male	**99**	0.3	**15.0**	10.5	**159**	**8.1**	**108**	*<5.0*	**3.3**
3-4 male	**27**	0.3	**13.2**	--	**150**	--	90	*<5.0*	**3.3**
3-4 male	**84**	**0.6**	**13.8**	9.6	144	**9.6**	**108**	*<5.0*	--
5+ male	**84**	**0.6**	**13.8**	**9.6**	144	**9.6**	**108**	*<5.0*	**4.2**
0-2 female	**220**	0.3	16.0	10.8	**152**	**6.8**	100	*<5.0*	2.8
5+ female	**366**	**3.2**	**30.2**	**12.2**	142	**8.8**	*92*	7.2	**3.6**
5+ female	**164**	**1.4**	**11.8**	--	**154**	--	106	*<5.0*	2.8
5+ female	**218**	**1.8**	**23.6**	**10.9**	141	**37.8**	**114**	10.0	--

[a] 0-2 week old (0-2), 3-4 week old, and 5+ week old (5+) *mgb-/-* mice. Chemistry values are statistically increased (bold), or decreased (italic) from normal (plain). --error recorded. BUN/ Creatinine/Phosphorus/Calcium=mg/dl; Na/K/Cl=mEq/L; Bicarbonate=mmol/L; Albumin=g/dl

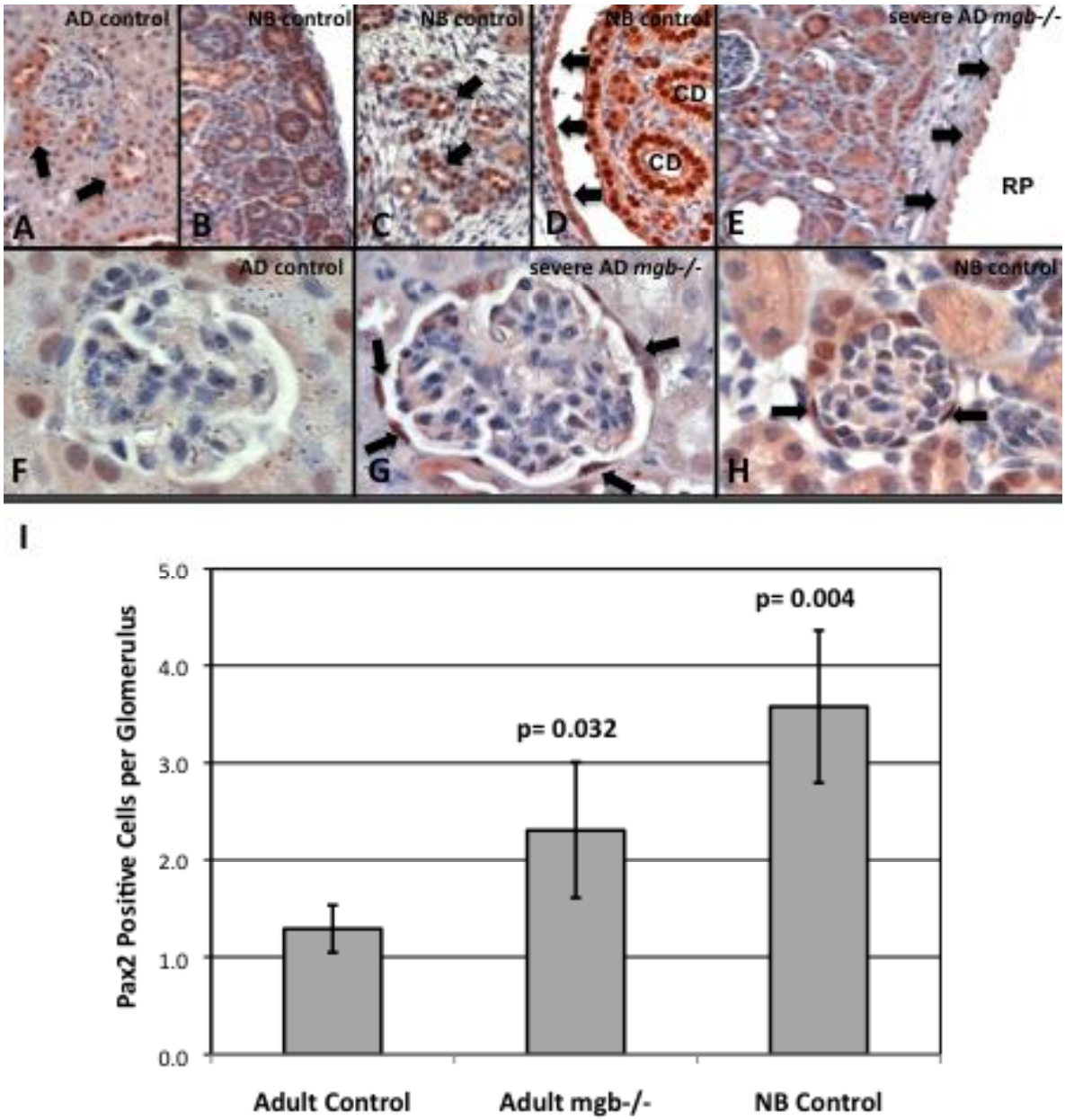

Figure 3: Representative Pax2 expression in newborn and adult kidneys. (A) Adult control kidney shows minimal Pax2 staining in cortical ducts (arrows), 20X. NB control kidneys show Pax2 staining in immature nephrons (B), cortical ducts (C), collecting ducts of renal papillae (D, CD), and urothelium of the renal pelvis (D, arrows), 40X. (E) Severe adult *mgb-/-* kidneys show expanded Pax2 staining in compressed parenchyma and urothelium of renal pelvis (RP, arrows) reminiscent of newborn control kidneys, 20X. (F) Severe adult *mgb-/-* kidneys show Pax2 positive cells within Bowman's capsule similar to the pattern observed in NB control (G) versus adult control (H). 100X. Individual P-values are compared to adult control.

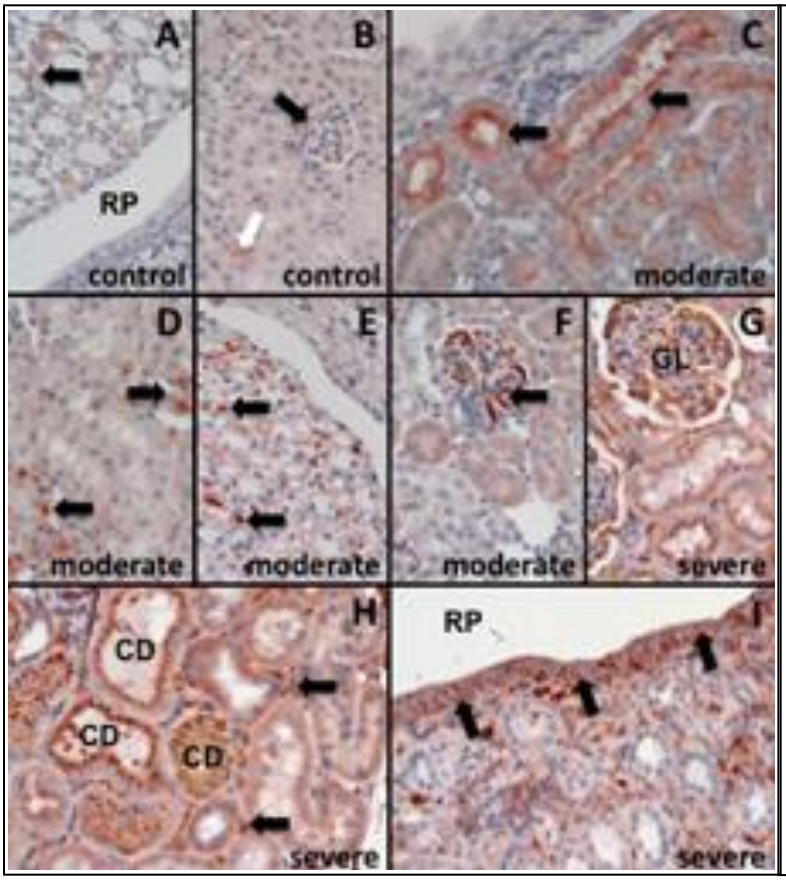

Figure 4: Representative TGFβ1 expression in adult kidneys. Control kidneys show TGFβ1 staining in the collecting ducts (A, arrow), interstitial cells (B, white arrow) and glomeruli (B, black arrow). Moderate mgb-/- kidneys show expanded TGFβ1 staining within cortical ducts (C, arrows), cortical and medullary interstitial cells (D,E, arrows), and glomeruli (F, arrow). Severe mgb-/- kidneys show expanded TGFβ1 staining in glomerular cells (G, GL), cortical ducts (H, CD), interstitial cells (H, arrows), and urothelium of the renal pelvis (I, arrows; RP), 40X.

Table 2: Status of *mgb-/-* mice after cutaneous vesicostomy

Animal	Age At Surgery (Days)	Status/Cause of Death
1869	32	lived several months and bred well
1923	39	lived several months and bred well
2021	42	lived for about 3 months
2309	31	lived for about 3 months (did not breed well)
2264	28	sacrificed at 14 weeks of age but looked well
2409	27	alive, stoma patent, thriving at 15 weeks of age
1986	19	apparent renal failure
1987	19	apparent renal failure
1988	16	apparent renal failure
1989	16	apparent renal failure
1999	26	apparent renal failure
2298	59	apparent renal failure
2299	60	apparent renal failure
2419	30	apparent renal failure
1933	63	medical demise, morphine overdose
1998	33	surgical complication, wound dehiscence
2008	28	surgical complication, bladder prolapse
2348	27	surgical complication, uroperitoneum
2349	27	surgical complication, bladder prolapse